

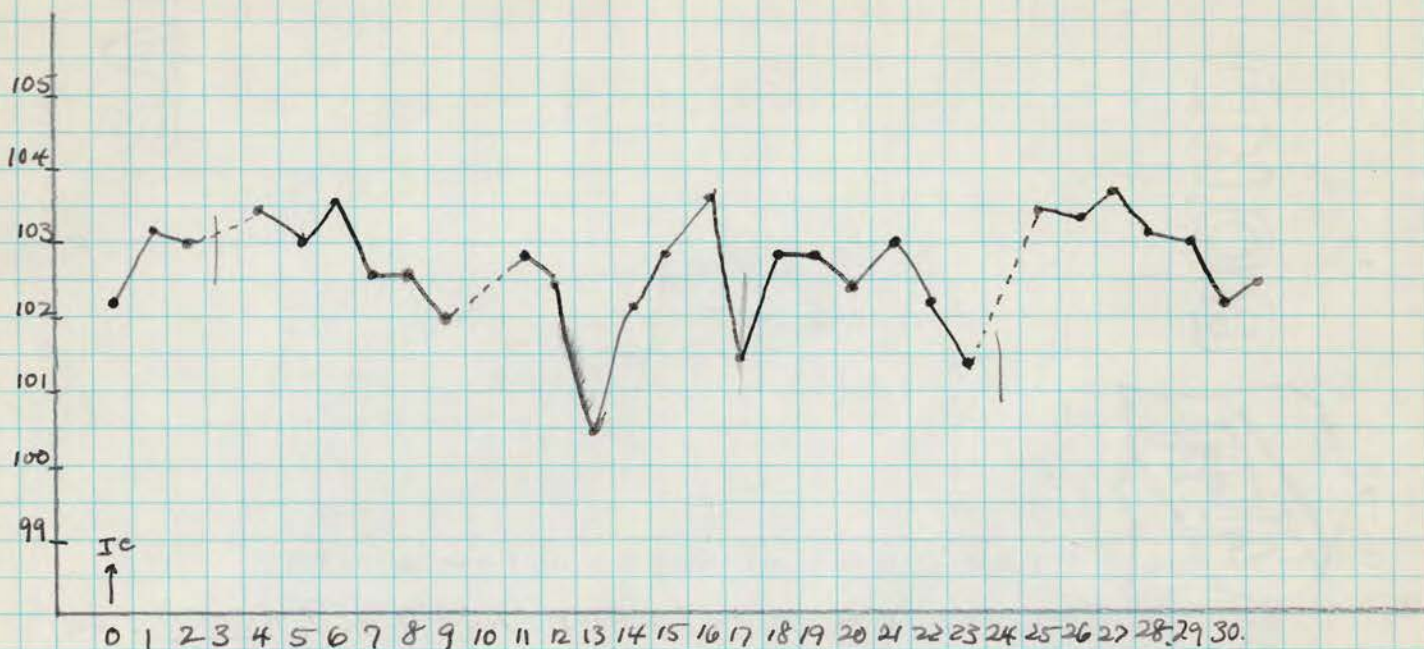
HOMOLO

OCT 7 1948

Challenge Re-inoculation with Homologous Polio Virus.

Rh. 631 -

convalescent.

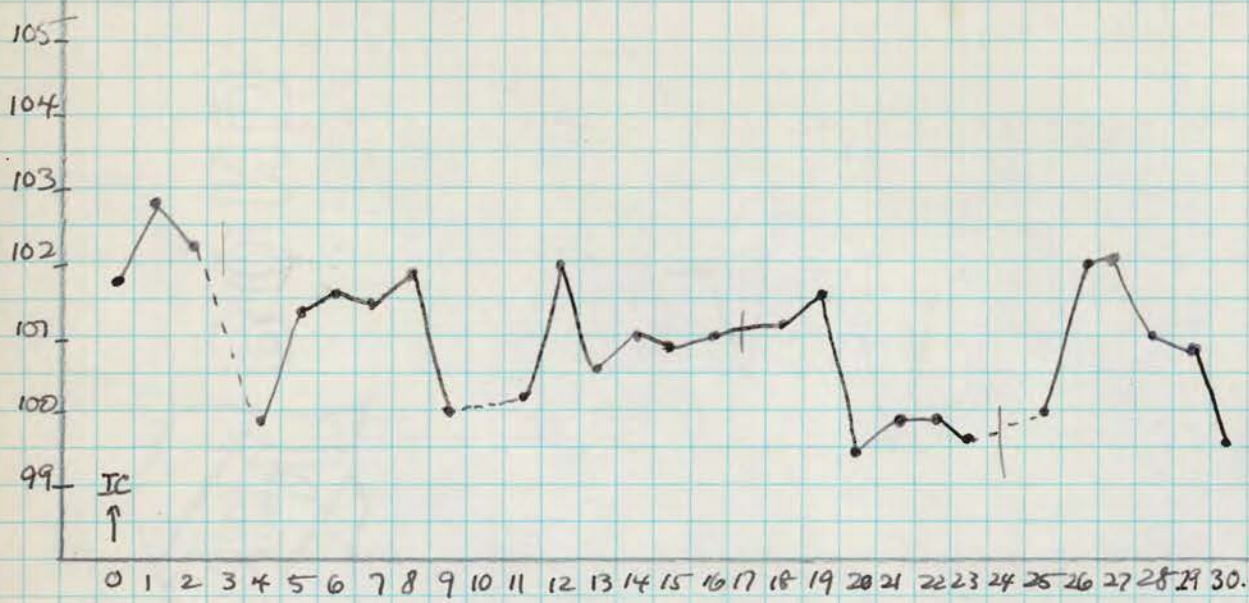

OCT 7 1948 - Challenged by right frontal ino. of 1.0 cc of 20% [redacted] polio virus. (rial #1 of Ben. III fragm 6/25/48); simultaneous control is Rh. 779X (g.v.); date original inoculation was 6/18/48. -

CONDITION WHEN CHALLENGED: Partial paralysis of both lowers with atrophy bilaterally R > L; uppers normal; very active; climbs well. -

11-8-48. Challenged with Heterologous strain - using 100 PD₅₀ [redacted] strain polio virus; Rh. 884X - as control. (see record.)

OCT 7 1948 Challenge B2 - Inoculation with Homologous Polio Virus -
Rh. 1931 - [redacted] convalescent



OCT 7 1948 - Challenged by IC inoculation (rt side) of 1.0 cc of 20% [redacted] virus, (amp. #1 of 62n.iii (begin 6/25/48); simultaneous control is Rh. 779X (g.u.); date of original inoculation was 6/18/48.

CONDITION WHEN CHALLENGED: complete paralysis of both lowers with marked atrophy - monkey cannot sit up; partial paralysis of both uppers with marked atrophy of rt. upper, and mod. atrophy of left upper. Moves back + head well; feeds self.


11-8-48. Challenged with heterologous strain - using 100 PD [redacted] polio virus - using Rh. 884X as control. (see [redacted])

OCT 7 1948

Control Monkey - In [redacted]

Homologous Challenge of Rh. 631 and Rh. 1931

Rh. 779X (used previously in Tatumant test g.u.)



OCT 7 1948 - Subcultured IC with 1.0 cc of 20% [redacted] virus (Gen III), simultaneously with Rh. 631 and Rh. 1931. (Mild diarrhea present.)

10-12-48 - Partial paralysis of both uppers; weakness of both lowers, neck and back. - - Sacrificed - chloroform exsanguination - Autopsy: NOT BA

TISSUES FOR HISTOLOGY: segments lumbar and cervical cord (2-A).

11-17-48 tissues discarded