

INFORMATION TO USERS

This manuscript has been reproduced from the microfilm master. UMI films the text directly from the original or copy submitted. Thus, some thesis and dissertation copies are in typewriter face, while others may be from any type of computer printer.

The quality of this reproduction is dependent upon the quality of the copy submitted. Broken or indistinct print, colored or poor quality illustrations and photographs, print bleedthrough, substandard margins, and improper alignment can adversely affect reproduction.

In the unlikely event that the author did not send UMI a complete manuscript and there are missing pages, these will be noted. Also, if unauthorized copyright material had to be removed, a note will indicate the deletion.

Oversize materials (e.g., maps, drawings, charts) are reproduced by sectioning the original, beginning at the upper left-hand corner and continuing from left to right in equal sections with small overlaps.

ProQuest Information and Learning
300 North Zeeb Road, Ann Arbor, MI 48103-1346 USA
800-521-0600

UMI[®]

UNIVERSITY OF CINCINNATI

May 21, 1935

I hereby recommend that the thesis prepared under my supervision by Joseph T. Tamura

entitled "The Virus of Lymphogranuloma Inguinale, Its Cultivation, Its Antigenic Value as a Vaccine and Also in the Production of an Antiserum"

be accepted as fulfilling this part of the requirements for the degree of Doctor of Philosophy.

Approved by:

J. B. W. Perry.

THE VIRUS OF
LYMPHOGRANULOMA INGUINALE

JOSEPH T. TAMURA, M.Sc.
Cincinnati, Ohio

From the Department of Bacteriology and Hygiene, University of Cincinnati College of Medicine, and the Cincinnati General Hospital

Reprinted from

THE JOURNAL OF LABORATORY AND
CLINICAL MEDICINE
St. Louis

Vol. 20, No. 1, Page 393, January, 1935.

(Printed in U. S. A.)

CINCINNATI
UNIVERSITY
LIBRARY

UMI Number: DP16101

INFORMATION TO USERS

The quality of this reproduction is dependent upon the quality of the copy submitted. Broken or indistinct print, colored or poor quality illustrations and photographs, print bleed-through, substandard margins, and improper alignment can adversely affect reproduction.

In the unlikely event that the author did not send a complete manuscript and there are missing pages, these will be noted. Also, if unauthorized copyright material had to be removed, a note will indicate the deletion.

UMI[®]

UMI Microform DP16101
Copyright 2009 by ProQuest LLC
All rights reserved. This microform edition is protected against
unauthorized copying under Title 17, United States Code.

ProQuest LLC
789 East Eisenhower Parkway
P.O. Box 1346
Ann Arbor, MI 48106-1346

This is a reprint in full of the dissertation submitted to the Graduate School of the University of Cincinnati in partial fulfillment of the requirements for the degree of Ph.D., June, 1935.

UNIVERSITY
OF CINCINNATI
LIBRARY

THE VIRUS OF LYMPHOGRANULOMA INGUINALE*

ITS CULTIVATION, ITS ANTIGENIC VALUE AS A VACCINE AND ALSO IN THE PRODUCTION OF AN ANTISERUM

JOSEPH T. TAMURA, M.Sc., CINCINNATI, OHIO

A REVIEW of the literature reveals that all attempts to cultivate the etiologic agent of lymphogranuloma inguinale have been failures. We have recently¹ succeeded in doing so by utilizing the medium devised by Maitland, Laing, and Lyth² for the cultivation of Vaccinia virus. This medium is made by placing sterile bits of rabbit tissue, kidney, liver, or spleen, in Berkefeld-filtered Tyrode's solution. We have used guinea pig tissue in place of rabbit.

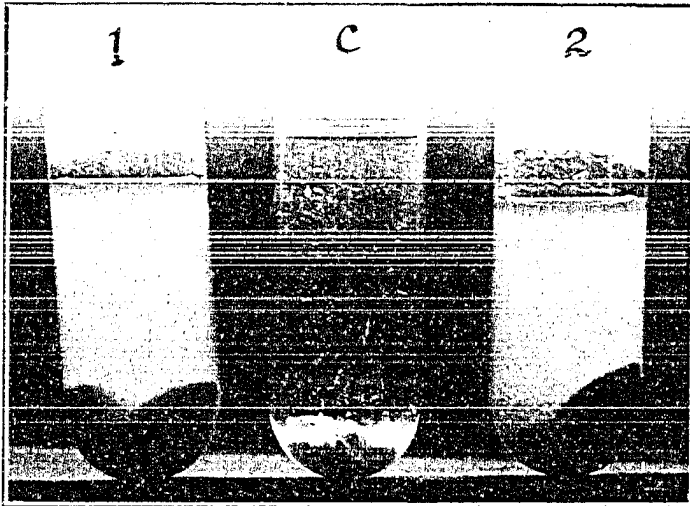


Fig. 1.—Cultivation of lymphogranuloma inguinale virus. 1, fourteenth subculture from Case C.R. C, control. 2, twelfth subculture from Case H.S., five days' incubation.

The inoculum, pus, is obtained from a fluctuant inguinal node that has not been exposed to external contamination. This pus is found to be bacteriologically sterile. It is diluted 1:5 with sterile saline solution. When from 0.02 to 0.03 c.c. of the diluted pus is planted in 7 c.c. of Tyrode's solution, containing a piece of guinea pig kidney or liver and incubated at 37.5° C., aerobically a peculiar cloudiness appears throughout the supernatant fluid in thirty-six to forty-eight hours. Control tubes of the medium, incubated in the same manner, remain perfectly clear. This cloudiness is transmissible from one subculture to the next. Fig. 1 illustrates this peculiar formation of cloudiness in the media. In our work the cloudiness was carried through 24, 14, and 12 subcultures when the procedures were discontinued.

*From the Department of Bacteriology and Hygiene, University of Cincinnati College of Medicine, and the Cincinnati General Hospital.

Received for publication, June 2, 1934.

In our experience, as in that of others, cultures made from bubonic pus when planted on a wide variety of bacteriologic media and grown aerobically, at partial oxygen tension, or anaerobically, remain free of visible growth. The cloudiness in the tissue-Tyrode medium remains for twelve- to fourteen-day incubation periods, after which the cloudiness seems to precipitate out and the supernatant fluid becomes clear and slightly straw colored. When this clear supernatant fluid, which has been cloudy once, is subcultured, it no longer produces cloudiness.

When the cloudy supernatant fluid is examined or cultured nothing resembling ordinary bacteria is to be found. Attempts to see the etiologic agent in cloudy fluid have failed with the exception that peculiar granules are brought out by Giemsa's stain and by eosin-Giemsa method originated by Hosokawa³ for the staining of a variety of viruses. Hosokawa's method of staining viruses, which we used, is as follows:




Fig. 2.—Cloudy supernatant culture fluid stained with Hosokawa's method, mounted in hyrax. A, Dark-field, reduced from a photomicrograph of 1500 diameters. B, Direct illumination, reduced from a photomicrograph of 1100 diameters.

1. *Smearing*: Loopful cloudy supernatant fluid is smeared as thin as possible on a perfectly clean slide by means of drawing it lengthwise by a second slide, as in blood smear preparation. The smear is air dried.

2. *Fixation*: The smeared film, after thorough drying in air, is fixed for two minutes in the fixing solution, then washed in water.

The fixing solution:

Methyl alcohol	100.0 c.c.
Formalin (original solution)	5.0 c.c.
Glacial acetic acid	1.0 c.c.

3. *Treating with eosin*: Flood the fixed slide with 1 per cent eosin solution and heat it over a flame for from one-half to one minute until it just steams, as in the case of staining acid-fast bacilli. Wash with water carefully.

4. *Giemsa staining*: Three drops of stock Giemsa in 2 c.c. distilled water is used. Hosokawa solution gave better results. This solution is prepared as follows:

Eosin methylene blue	2.0 gm.
Azure I	0.4 gm.
Crystal violet	0.025 gm.

Dissolve in 250 c.c. of equal parts of methyl alcohol and glycerin; filter through paper.

One c.c. of the stock solution is diluted in 50 c.c. of distilled water just before using. Fixed and eosin-treated slides are stained from fifty to seventy minutes at room temperature, are washed in water and dried in the air.

It is found that not all of the bubonic pus from the patients produce cloudiness of the medium. When pus from patients that fails to produce cloudiness in media is used to prepare Frei antigen, this antigen fails to give positive skin reactions in proved cases. Subcultures from a 1:10,000 dilution of pus failed to produce cloudiness, but from a 1:1,000 dilution yielded growth. When diluted pus or the cloudy supernatant fluid in culture is passed through a

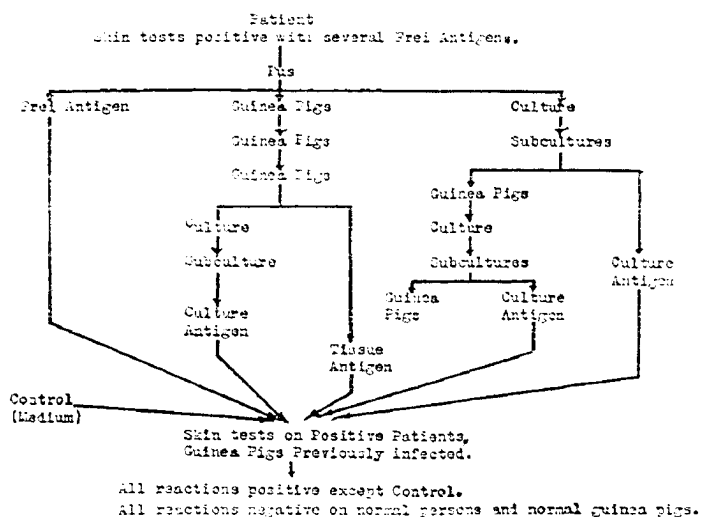


Chart I.

Berkefeld "N" filter the filtrate will produce cloudiness on subculture. When 1 c.c. of the cloudy supernatant fluid is inoculated into the groin of a guinea pig, a lymphadenitis is produced in from two to three days. The glands gradually increase in diameter and after ten to twelve days will become conglomerate masses of glands and may measure 15 mm. or more in diameter. The overlying skin becomes adherent to the affected nodes, after which they tend to disappear spontaneously. The skin sensitivity of the animals will develop in from three to four weeks. This is comparable to that which one can accomplish by direct inoculation with human pus. Such culture inoculations were successful when the fourth, sixth, and eighth subcultures were used. The etiologic agent has been passed from culture to guinea pig, then from guinea pig to the medium, from this culture to a subculture and then back to the guinea pig. Chart I illustrates the complete cycle of animal inoculation.

The cloudy supernatant fluid from a subculture was heated to 60° C. for two hours on one day, and at the same temperature for one hour on the fol-

lowing day, as in the well-known method of preparing Frei's antigen from pus. When such heated culture antigen, preserved with 1:10,000 merthiolate, is injected intradermally into patients it gives just as marked reactions as does the Frei antigen. When the twenty-third subculture in one series was heated for antigen it was found to be just as active as antigen prepared from earlier subcultures. As in the case with Frei's antigen, the culture antigen gives no reaction in normal individuals.

An attempt has been made to produce lymphogranuloma inguinale antiserum from a goat with heated culture antigen. Beginning on Dec. 1, 1933, and continuing to March 28, 1934, a total of 81 c.c. of the antigen was injected into the animal subcutaneously. The animal was bled on April 6, and 145 c.c. of serum was obtained. Merthiolate, in 1:10,000 concentration was added as preservative. Gottlieb⁴ reported experimental evidence to show that there are in the serums of patients recovering from lymphogranuloma inguinale substances which have neutralizing properties on the Frei antigen when this is used for skin tests. In our work intradermal injections were made into lymphogranuloma inguinale patients of (1) Frei antigen, (2) saline, (3) Frei antigen plus normal goat serum, (4) Frei antigen plus antilymphogranuloma inguinale goat serum, after the mixture had been kept under refrigeration for forty-eight hours. (1) and (3) gave positive reactions while (2) and (4) were negative. This antiserum from the goat has been used for the treatment of two patients, reported below.

Through the courtesy of the Department of Dermatology of the Cincinnati General Hospital we are able to present thirteen cases we have treated using heated culture antigen as a vaccine administered subcutaneously, and two cases treated with antiserum. Eleven cases, including one serum-treated case, showed such marked improvement that they were considered cured in an average of eight weeks. Usually the vaccine is given with an initial dose of 0.2 to 0.3 c.c., which gives strong local reaction. Each subsequent injection produces a smaller and smaller response. The tolerance to larger doses given later is believed to be due to desensitization. Accompanying the clinical improvement there was a marked reduction in skin sensitivity. Of the remaining four cases, three are chronic and one has been treated for only two weeks. These appear to be following a similar favorable course. Beneficial therapeutic effects following the intradermal inoculation of Frei's antigen have been reported recently by Wien and Perlstein⁵ who refer to the previous work of Herman and Gay-Prieto. Brief accounts of several cases follow. Treatment of four cases with heated culture antigen.

CASE 1.—E. T., negro male, single, twenty years of age. He was first seen on Dec. 14, 1933. There were two chains of swollen glands in the right groin, measuring 5 by 2 cm., and 7 by 2.5 cm. There were no palpable masses in the left groin. Patient first noticed the "swelling of groin" in latter part of September, 1933, and had been under treatment since October 4 by various physicians. There was no history of syphilis and Wassermann reaction was negative. Gonococcus infection one year ago. Frei skin tests strongly positive. Beginning December 18, with initial dose of 0.1 c.c., a total of 22.7 c.c. of vaccine was given, in 30 inoculations. Considerable reduction in skin sensitivity was obtained. On March 3, when the last inoculation was given, both chains of nodal masses had disappeared completely. No remission has occurred in two months.

CASE 2.—T. D., white male, single, twenty-seven years of age. He was exposed to infection Dec. 17, 1933. Onset of swelling in left groin was first noticed Jan. 2, 1934. Admitted to hospital January 19, and seen on January 31. There was tenderness on palpation of the affected glands, which measured 6 by 3 cm. The skin was attached to the




Fig. 3.—Frei skin tests, Case T.D., *Smith*. Antigen prepared from *Smith*. *Jones*, Antigen prepared from *Jones*. *F₆*, Culture antigen (sixth subculture). *Control*, Tissue Tyrode medium.

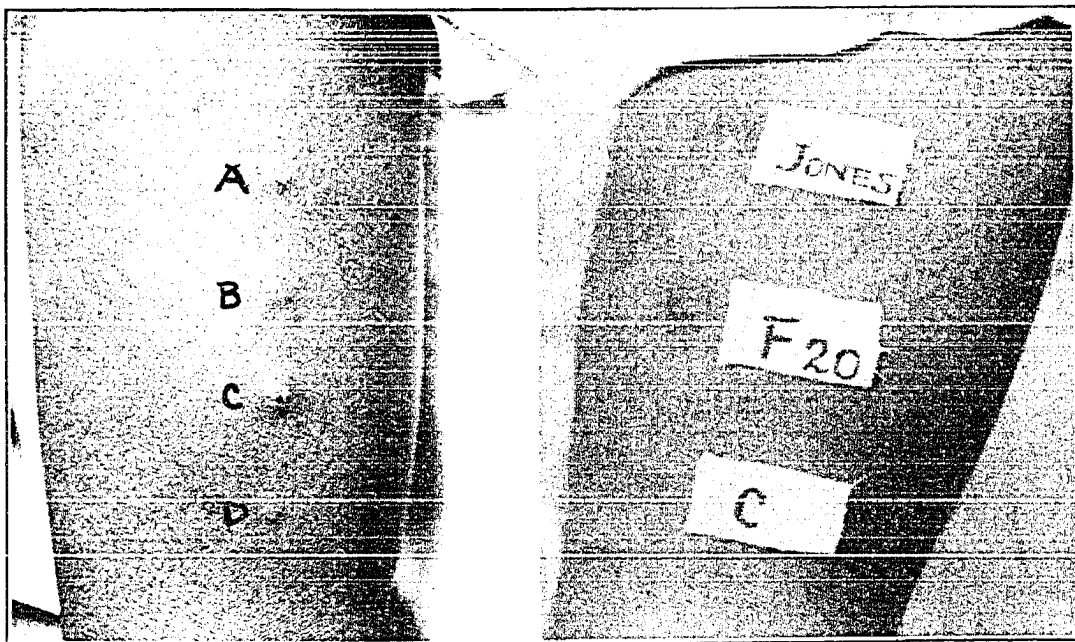


Fig. 4.—Left, Case R.S. *A*, Frei antigen. *B*, Frei antigen. *C*, Culture antigen (sixth subculture). *D*, Control with tissue Tyrode medium. Right, Case E.T. *Jones*, Frei antigen. *F₂₀*, Culture antigen (twentieth subculture). *C*, Control, tissue Tyrode medium.

underlying nodes, dark reddish purple in color. No masses in right groin. No history of syphilis, and Kahn test negative. Frei skin tests markedly positive. The nodes suppurated and pus was aspirated on February 14, 3 c.c., and again 2 c.c. on February 20. Bacteriologic examinations of the pus, made twice, were entirely negative. Beginning Feb-

ruary 1 and continuing to April 5, 25 subcutaneous injections of vaccine were given, totaling 22 c.c. Skin sensitivity was reduced to a negligible degree. When last seen, on April 18, there were no palpable masses.

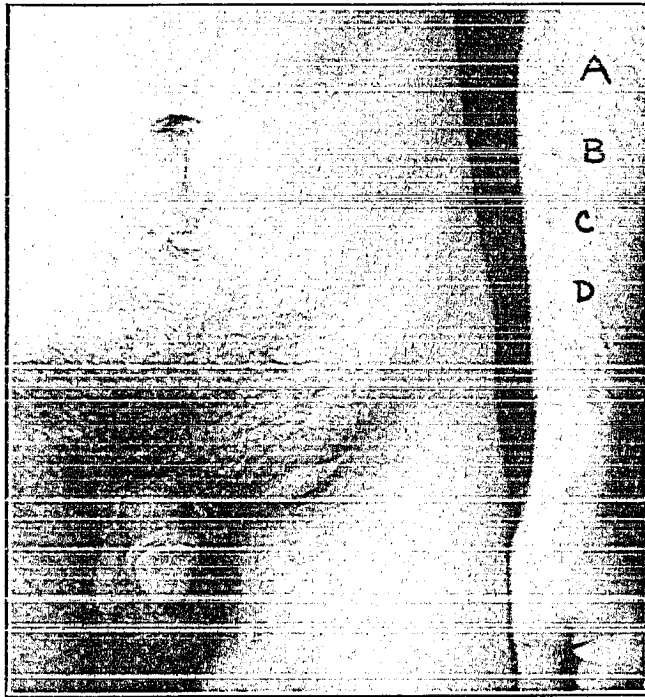


FIG. 5.—Unilateral lymphogranuloma inguinale. Positive Frei reactions on arm. A, Frei antigen. B, Culture antigen (fifteenth subculture). C, Frei antigen. D, Control with tissue Tyrode medium.

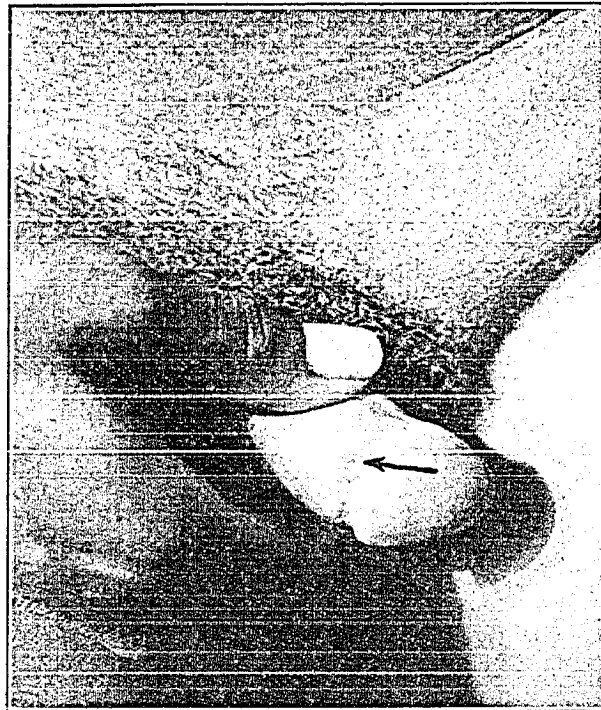

FIG. 6.—Unilateral lymphogranuloma inguinale; Case R.S., aged seventeen. Arrow points to characteristic primary lesion.

TABLE I*
GIVING DATA ON TEN CASES NOT REFERRED TO IN TEXT

CASES	AGE, SEX, COLOR	DATE OF ONSET	INCUBATION PERIOD (DAY)	DURATION (WEEK)	PRIMARY LESION	INGUINAL ADENITIS	SUPPURATION	FISTULATION	LENGTH OF TREATMENT (WEEK)	NUMBER OF INJECTIONS	TOTAL VACCINE GIVEN (C.C.)	WASSERMANN OR KAHN REACTIONS	RESULTS
R. S.	17 M. B.	12/25/33	10	4	+	U	+	+	10	27	25.4	-	C
A. R.	19 M. B.	1/19/34	14	3	+	U	-	+	9	26	27.0	-	C
H. K.	19 M. B.	2/8/34	7	8	-	B	-	-	5	11	8.3	-	C
C. F.	28 M. W.	3/15/34	10	2	-	U	+	+	7	21	16.0	-	C
R. M.	31 M. B.	2/19/34	9	6	-	B	-	-	6	17	10.0	-	C
S. B.	35 M. B.	3/9/34	?	3	+	U	+	L	8	16	11.5	-	C
B. R.	18 M. B.	July, '33	?	24	?	B	+	+	17	40	32.0	-	G. I.
H. S.	46 M. B.	Jan., '34	?	10	?	U	+	-	8	21	16.0	?	I
G. S.	26 M. B.	4/22/34	14	2	+	U	+	L	2	3	Anti-Serum 60.0	?	G. I.
J. W.	39 F. B.	July, '33	?	36	?	U	+	+	9	27	16.3	-	G. I.

*Keys to the Table: U, Unilateral. B, Bilateral.
C, Cured. I, Improved.
L, Lanced. I and G. I., still under treatment.
G. I., Greatly Improved.

CASE 3.—C. S. J., negro male, single, thirty-one years of age. He had had inguinal adenitis for about two weeks when he was first seen, on December 28. Markedly swollen, fluctuant nodes in the right groin. No masses in the left groin. He had had gonorrhoea four years ago and again four months ago. No lesion on or discharge from the penis. Kahn reaction 2-plus. Frei tests markedly positive. He was admitted to the hospital December 28. On the next day 5 c.c. of pus were aspirated from the fluctuant nodes. Dark-field examination for treponemas was negative; cultures negative. The suppurating nodes ruptured spontaneously January 2. Patient discharged from hospital January 12 and readmitted January 29. The nodes were very swollen and tender and there was a small fistula from which purulent material was discharging. Vaccine therapy was begun January 29, with initial dose of 0.3 c.c. A total of 25.5 c.c. of vaccine was injected in 28 inoculations. Patient resumed his occupation as a porter on March 17, and when last seen on April 9 the fistula was healed and masses of nodes were no longer palpable.

CASE 4.—F. M., negro male, married, thirty years of age. He was seen January 11. He had bilateral inguinal swellings. Indurated masses of nodes measured 6 by 2 cm. on left, and 7 by 2.5 cm. on right. The swelling was first noticed by the patient on December 25.

Ten days preceding the onset he was exposed to infection. There was no sore on the penis. Gonorrheal infection two years previously. Kahn reaction negative. Frei skin tests strongly positive. The nodes never suppurated. Beginning January 13, a total of 19 c.c. of vaccine was given in 22 subcutaneous injections. Marked desensitization was obtained. The masses of nodes had completely disappeared from both groins by March 5. He resumed his occupation as a porter on this date, and has had no remission for three months.

Treatment of one case with goat antiserum.

CASE 5.—C. R., white male, single, 25 years of age. He was seen first February 8, with markedly swollen nodes in left groin, measuring 10 by 5 cm., very tender and painful. Swelling of groin was first noted January 26, a week or ten days after he was exposed to infection. No primary lesion found. Slight urethral discharge, which upon examination was found to be gonorrheal. Kahn reaction 3-plus. Frei skin tests strongly positive. The involved nodes suppurated and pus aspirated: February 17, 3 c.c.; February 19, 3 c.c.; February 24, 6 c.c.; February 26, 6 c.c., and March 1, 8 c.c. Bacteriologic examination of the pus negative. Patient was admitted to hospital March 1. Beginning February 10, 9.4 c.c. of vaccine was given subcutaneously in 13 inoculations. On March 8, the nodes were incised and curetted, when vaccine therapy was discontinued. Seropurulent discharge continued and wound did not heal. Swelling of suprapubic nodes noted April 7. Patient was dismissed from hospital on April 10, readmitted on April 18, when the suprapubic nodes were incised and curetted. Continuous drainage followed. Skin test with a goat serum was negative on April 23; followed by 20 c.c. of antiserum intravenously. Twenty cubic centimeters of antiserum was given again on the twenty-fourth, and 15 c.c. by vein on the twenty-sixth. Serum sickness occurred on the twenty-ninth and lasted thirty-six hours. Patient was discharged from hospital May 4. Drainage had ceased and epithelialization had occurred. Two weeks after the first serum injection the wound was completely healed.

SUMMARY

When pus from the lymphogranuloma inguinale is planted in the medium devised by Maitland and his coworkers for the cultivation of Vaccinia virus, the medium becomes cloudy. The etiologic agent produces a cloudiness which is transmissible in serial cultures, or serial cultures alternating with guinea pig inoculations. The etiologic agent in pus or in cloudy supernatant culture fluid passes the Berkefeld "N" filter. The virus is stainable by Hosokawa's eosin-Giemsa method. The heated cultures have been used successfully in making diagnosis by the intradermal skin test, and in inducing recoveries by subcutaneous inoculations. Also heated cultures have been used to produce an antiserum. Although one can draw no definite conclusions from the few cases treated with antiserum, the results in these cases justify further trial of serum therapy.

REFERENCES

1. Tamura, J. T.: Preliminary Note on the Cultivation of the Virus of Lymphogranuloma Inguinale; Its Use as a Vaccine and in the Production of an Anti-serum, *J. A. M. A.* 103: 408, 1934.
2. Maitland, H. B., Laing, A. W., and Lyth, R.: Observations on Growth Requirements of Vaccinia Virus in Vitro, *Brit. J. Exper. Path.* 13: 90, 1932.
3. Taniguchi, T., Hosokawa, M., Kuga, S., and Fujino, T.: A New Method of Staining Viruses of Variolo-Vaccinia and Varicella, and the Nature of Cell-Inclusions in Virus Diseases, *Jap. J. Exper. Med.* 12: 91, 1934.

4. Gottlieb, F.: Neutralisation du virus de lymphogranuloma inguinale par le sérum des malades en voie de guérison. *Compt. rend Soc. de biol.* **111**: 141, 1932.
5. Wien, M. S., and Perlestein, M. O.: Intradermal Treatment of Lymphogranuloma Inguinale. *Arch. Dermat. & Syph.* **28**: 42, 1933.