

IV
1170
1171
1172
1173
1176

for monkeys 1171 and 1172

No drug on Dec 4 and 5


98 OK. on Dec. 6 and Temp 101 or over

Give regular drug schedule for this group one day
and observe

Rh 1170 - Virus host, followed by INTRAMUSCULARLY GROUP III
ISOPLASMOCID

Procain penicillin - 300,000 U
intramuscularly once a day

107
106
105
104
103
102
101
100
99
98
97
96
Drug
Dec.



No neuronal lesions found

0 1 2
MMM
2 3 4

DEC. 2 - VIRUS @ 3:30 PM.
Drug intramuscularly @ 5:30 PM. - developed no neur. signs

Dec. 3 - 2nd dose @ 1 AM.
9 A.M. - exhibits pilomotor response, but otherwise appears alert and ok.

DEC. 4 - @ 8 AM - found dead - still warm.
Perfusion started about 11 AM
Very poor - although only by gravity, entire animal swelled up.

It was not until 5 PM - that the CNS was removed - the brain, basal ganglia and lumbar cord were not fixed at all. The cervical cord partly and the medulla very slightly. Sections in Z.A.

The viscera showed no abnormal changes
No pulmonary oedema

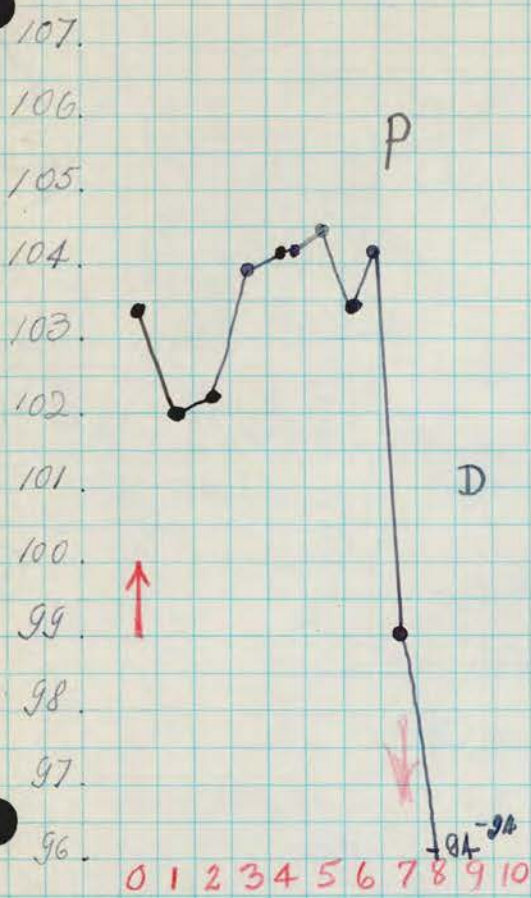
DEC. 5 - 9⁴⁵ AM - New cuts in Z.A. just 6 PM - washing

Rh. 1171 - Virus followed by 150 PLASMOCID
INTRAMUSCULARLY

GROUP IV

Procain penicillin - 300,000 U
intramuscularly once a day

Polio



Drug M M M - - M M M M M M M M -
Dec. 2 3 4 5 6 7 8 9 10 11 12

- Dec. 2 - ~~Drug~~ Virus about 3:30 PM.
Drug - 1st dose about 5:30 PM. - Within 10 minutes began to have moderate generalized convulsions which continued ~~about~~ several hours - but had stopped by midnight
- Dec. 3 - @ 12:30 - 1 AM - 2nd dose of drug given - no convulsions
9 AM - hair very erect on head and body; excited
2:30 PM - condition same.
- Dec. 4 - 9 AM - Condition same but because other monkeys in this group are very ill - drug was discontinued
- Dec. 5 - Same condition -
- Dec. 6 - Hair very erect on head and body - loss ~~loc. 7 minute~~ drug given again:
9 AM - 6th dose - intramuscularly (scheduled)

Not combusting:
2³⁰ Excited - Pilomotor.
DEC. 7 - Pilomotor on head, shoulders
and arms
9 AM Drug given (Scheduled amount)
3 PM " "
9 PM " "

DEC 8 - 9 AM Chin - 103.4
Drug given
2:30 PM 104.2 - Same condition
3:00 PM Drug given -
9:00 PM Drug given.

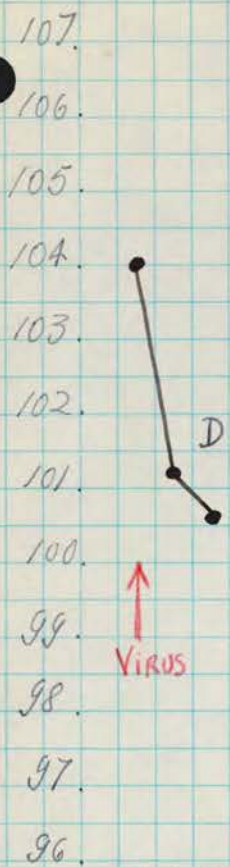
DEC. 9 - 8:30 Very weak
Lies on floor. Flaccid paralysis
both upper. Partial paralysis
both lower.
NO DRUG - 99° - DISCONTINUED.
9 PM Same condition.

DEC. 10 - 9 AM - 94° - Same condition
3 PM - Same condition
9 PM - Complete quadriplegia.
Back and neck also pa-
ralyzed

DEC. 11 - 9 AM Same condition.
7 AM -
8:30 PM - Head still warm.
Immediate autopsy.
Viscera normal. No pulm. edema.
CNS → Z.A.

Rh 1172 Virus followed by 150 PLASMOCID
INTRAMUSCULARLY. GROUP IV

Procain penicillin - 300,000 units
intramuscularly once a day



No neuronal lesions

0 1 2 3 4 5 6 7 8

DRUG MM

DEC. 2 3 4 5 6 7 8 9 10

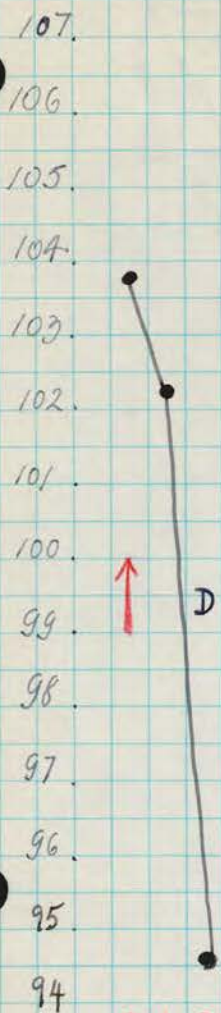
- Dec. 2 - Virus given @ 3:30 PM.
1st dose of drug @ 5:30 PM. — No convulsions
- Dec. 3 - Sits quietly in cage - and dozes off (closing eyelids) when undisturbed. Wakes up on slightest disturbance but doesn't move very much.
- Dec. 4 - 9 A.M. - more somnolent and lethargic than before
Drug not given
3 PM - same
8:40 PM - Found dead - still warm as if just died
Immediate Autopsy - No gross pathological changes on vis-
cava. CNS → Z.A.
- DEC. 5 - New cuts, continuous in Z.A just 6 PM - washing.

Rh 1173

Virus followed by 150 PLASMOCID
INTRAMUSCULARLY

GROUP IV

Procain penicillin - 300,000
intramuscularly once a day



Tissue well fixed + stained
No "neuronal" lesions of
any kind seen in midbrain
medulla, spinal cord, or
cerebral cortex

0 1 2 3 4 5 6 7 8 9 10

DRUG

MMM

DEC 2 3 4 5 6 7 8 9 10

DEC. 2 - Virus given about 3:30 PM.

First dose of drug about 5:30 PM - slight convulsive seizures
noticed within 10 minutes

Dec. 3 - ~~at~~ 12:30 AM - No Convulsions - 2nd dose of drug
not followed by convulsions

9 AM - appears ok.

2:30 PM - " "

DEC. 4 - 9 AM - lying down in cage - appears very ill - no neuro signs
Drug not given

3 PM - Difficult respiration - appears terminal

4 PM - died.

Autopsy done within 30 min. - no perfusion
Tissues very firm. Sections in Z. A.
Viscera OK. No pulmonary edema.

Rh 1176

Virus followed by
INTRAMUSCULARLY

GROUP IV
ISOPLASMOCID

Procain penicillin - 300,000
intramuscularly immediately
before Isoplasmoacid

Tissue poorly fixed but
no evidence of neuronal
lesions of drug toxicity
type

107.

106.

105.

104.

103.

102.

101.

100.

99.

98.

97.

96.

DRUG ↑

DEC 2 3

Dec. 2 - Virus given about 3:30 PM

1st dose of drug about 5:30 PM - Within 5 min. developed
very severe generalized convulsions which
continued without cessation

Dec. 3

1:30 A.M - condition same

3:00 A.M - " " ; appears very weak

7:00 A.M - found dead in rigor.

Necropsy

Brain and cord - markedly congested.

Portions put in 2.A.

Dec. 4 - Washing

Dec. 5 - Alcohol 70%

Dec. 6 - New cuts in 80%

Material incomplete